# *TBL-3*

1- A 32-year- old woman with insomnia undergoes an electroencephalogram (EEG) in a sleep disorder clinic. At 3:00 AM, the EEG technician notes that the women's recording was exhibiting sleep spindles and K complexes. Which stage of sleep is she in at this time?

A. REM
B. Stage 1
C. Stage 2
D. Stage 3
E. Stage 4

2- Which of the following EEG rhythm, if recorded from an awake young adult, will be indicative of serious brain damage?

A. Alpha rhythm
B. Beta rhythm
C. Theta rhythm
D. Delta rhythm
E. Gamma rhythm

3- A patient is confused and displays localized jerks in his right hand, which progress to jerks of the entire arm with a brief loss of consciousness. This disorder can best be characterized as a;

A. Generalized seizure
B. Absence seizure
C. Simple partial seizure
D. Complex partial seizure
E. Atonic seizure

4- A 63 year old man has been bothered by shaking of his hand at rest and generalized stiffness of his body, which have become progressively worse during the last three years. On entering the examining room he moves slowly and deliberately, shuffling his feet, his shoulders and trunk are stooped forward and his arms at side not swinging. He has mask like face and resting pill rolling tremor. Neurons in which of the following areas of brain may have degenerated in this case.

A. Caudate nucleus
B. Globus pallidus externa
C. Globus pallidus interna
D. Substantia nigra reticulate
E. Substantia nigra compacta

5- A 35-year-old has an inherited progressive neuronal generation of brain. This resulted in twitching movement of head, grimacing movements in distal parts of upper limbs and jerking movements in distal parts of lower limbs. The neurons in which one of the following parts of the bran were degenerated in this patient.

A. substantia nigra compacta
B. globus pallidus externa
C. globus pallidus interna
D. subthalamus
E. Striatum

6- A 30-year-old woman complains of unsteadiness while standing and walking. She tends to deviate to the right, neurologic examination reveals dysmetria on the right side, dysdiadochokinesia, and nystagmus that is more marked when she looks to the right side. Where is the lesion located?

A. Right cerebellar hemisphere
B. Right flocconodular lobe
C. Cerebellar vermis
D. Right mesencephalic tegmentum
E. Left cerebellar hemisphere

7- A 20-year-old epileptic person is brought to ER with status epilepticus. An intravenous line was maintained and possible etiology of her condition was determined on history, physical examination as well as emergency blood and urine tests. Then, she was given intravenous lorazepam, repeated after five minutes. Her condition did not improve; therefore high dose phenytoin was given intravenously with cardiac monitoring. She did not respond well, hence intravenous phenobarbital was considered as the next step. Which one of the following would be the next logical step if phenobarbital is not effective?

A. Carbamazepam
B. General anesthesia
C. Lamotrigine
D. Sodium valproate
E. Topiramate

8- Which one of the following mechanism is not applicable to suppression of generalized tonic-clonic seizure, using the standard drug doses?

A. Increased duration of opening of neuronal chloride channels.
B. Increased frequency of opening of neuronal chloride channels.
C. Inhibition of calcium channels in basal nuclei
D. Inhibition of neuronal glutamatergic transmission
E. Inhibition of sodium channels

9- A 37- year old man who is suffering from AIDS has had increasing memory problems. During the past 3 months, he has had increasing problems with motor function and is now unable to stand or walk. MRI of the brain shows diffuse cerebral atrophy; no focal lesions are identified. On microscopic examination of the brain, which of the following findings is most likely to be present?

A. Plaques of demyelination in perventricular white matter
B. Neocortical senile plaques and neurofibrillary tangles
C. Multiple lacunar infarcts in basal ganglia and gliosis
D. Pick cells (ballooned neurons) pick bodies and gliosis
E. White matter perivascular accumulation of macrophages (microglial modules) with multinucleate cells.

10- A 45 year old woman noticed tinnitus in her right ear which progressed over 5 weeks to unilateral hearing loss. On physical examination, she has a marked decrease in hearing on the right. The other cranial nerves I-IV and IK-XII are intact. Brain MR imaging reveals a solitary, circumscribed 3 cm mass located in the region of the right cerebellopontine angle, which was resected and sent for histopathological analysis. Histologic sections from the mass would most likely reveal;

A. Antoni A areas and antoni B areas with verocay bodies
B. A whorled pattern meningoepithelial cells with scattered psammoma bodies
C. Endothelial profileration & nuclear pseudopalisading of atypical astrocytic cells
D. “Fried-egg” appearance of tumor cells with calcification
E. Small blue cells with homer wright rossetts.

11- A 70-year-old alcoholic man has exhibited problems remembering things for the past 7 months, and he is noted by his immediate family members to confabulate. He dies as a consequence of a hepatic failure. At autopsy, his brain demonstrates bilaterally small mammillary bodies revealing brown discoloration. Microscopically, there is gliosis and vascular proliferation and hemosiderin deposition in the mammillary bodies and periaqueductal grey matter. Which of the following is the most likely diagnosis?

A. Pick disease
B. Metachromatic leukodystrophy
C. Wernicke-korsakoff syndrome
D. Central pontine myelinolysis
E. Progressive multifocal leukoencephalopathy

12- Several members of a large family are affected by the onset of decreasing mental function and motor coordination when they reach middle age. Their extremity movements are marked by choreoathetosis. Genetic testing reveals increased trinucleotide CAG repeats. Which of the following intracranial structures is most likely to appear grossly abnormal with radiologic imaging of these affected persons?

A. Caudate nucleus
B. Midbrain
C. Temporal lobe
D. Locus ceruleus
E. Spinal cord

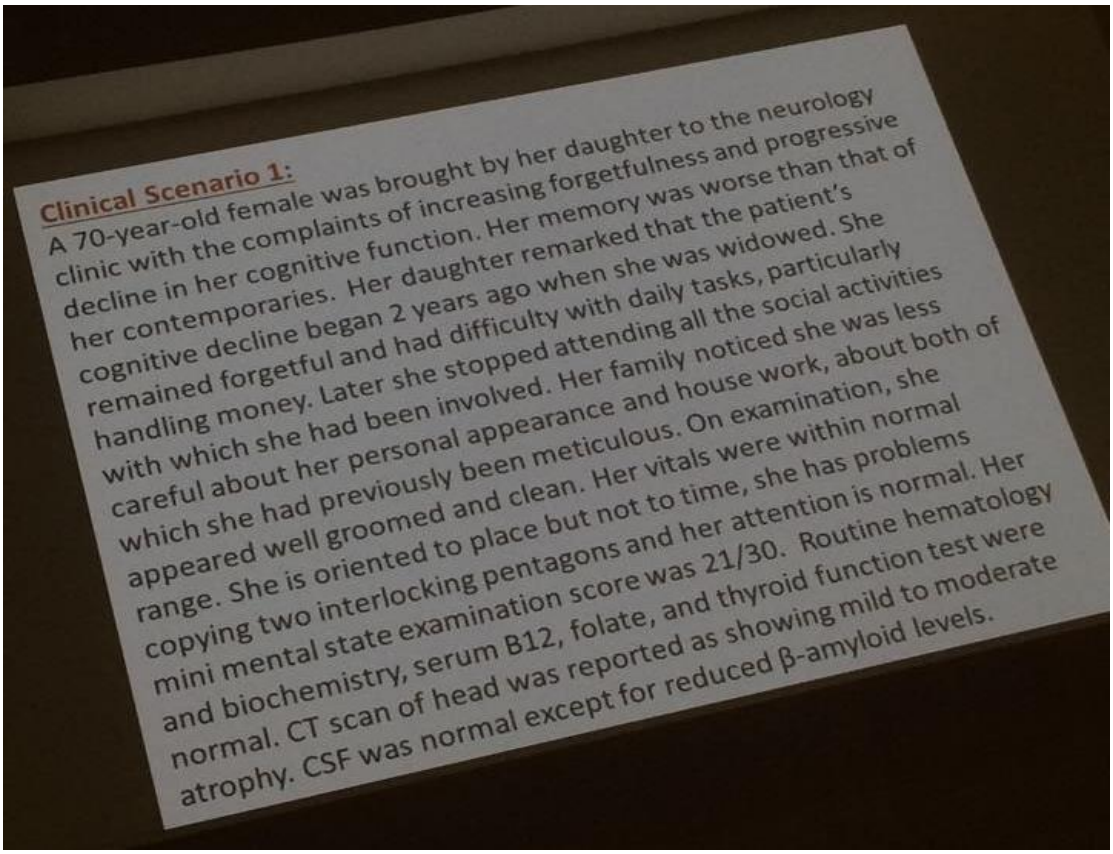

**Clinical Scenario 1:**

A 70-year-old female was brought by her daughter to the neurology clinic with the complaints of increasing forgetfulness and progressive decline in her cognitive function. Her memory was worse than that of her contemporaries. Her daughter remarked that the patient's cognitive decline began 2 years ago when she was widowed. She remained forgetful and had difficulty with daily tasks, particularly handling money. Later she stopped attending all the social activities with which she had been involved. Her family noticed she was less careful about her personal appearance and house work, about both of which she had previously been meticulous. On examination, she appeared well groomed and clean. Her vitals were within normal range. She is oriented to place but not to time, she has problems copying two interlocking pentagons and her attention is normal. Her mini mental state examination score was 21/30. Routine hematology and biochemistry, serum B12, folate, and thyroid function test were normal. CT scan of head was reported as showing mild to moderate atrophy. CSF was normal except for reduced β-amyloid levels.

Q1-Q5 are related to the clinical vignette:

1- What is the most probable diagnosis in this case?
   Alzheimer disease

2- List two differential diagnosis of this case?
   Vascular dementia & frontotemporal atrophy

3- Which artery is involved in this case?
   Middle cerebral artery

4- According to the most probable diagnosis made by you, what kind of pathological lesions are expected in the brain of this patint?
   Neurofibrillary tangles & senile plaques

5- when she was asked, "what is the capital of the kingdom of Saudi Arabia" she replied, 'Qaseem'. What kind of memory is being tested?
   Semantic memory

BEST OF LUCK
Mohammed Al-Azmah